

SURVIVAL OF A LARGE *CROCODYLUS POROSUS* DESPITE SIGNIFICANT LOWER JAW LOSS. *Memoirs of the Queensland Museum* 39(2): 338, 1996. On 25 May, 1995 a large (SVL 195.5cm; TL 424.5cm), male crocodile (*Crocodylus porosus*) was caught in the Nicholson River, NW Qld (17°44'S, 139°31'E). It was captured in a mesh trap, set under the supervision of the Department of Environment and Heritage. The crocodile had attacked and killed a dog. A significant portion of its dentary, including the symphysis to the region of the 10th and 11th tooth alveoli, had been lost. The right partial dentary, which closed first, was 7.5cm shorter than the left, resulting in an uneven closing of the jaws. The tongue had also been partially amputated, but had healed with a large egg-shaped growth at the anterior edge. This was apparently an area of scar tissue resulting from the trauma or from the inclusion of a bone fragment in surrounding tissue. The tongue appeared to be hypertrophied, probably as a result of its continued involvement in the closing and manipulation of the two dentary fragments. Rather than a normal, flat appearance, buccal edges were greatly enlarged, giving the tongue a pillowed appearance. This crocodile had sustained several other injuries, including scarring on the trunk in front of the hind limbs and amputation of the first and second metatarsals of the right foot. Many teeth were also missing from both lower jaws. (It was not possible to ascertain whether these had fallen out with age or wear, or had been broken during aggressive encounters with other crocodiles).

A wide variety of abnormalities and injuries have been recorded amongst crocodiles (Iordansky, 1973). Some studies of injuries have focussed on particular species (e.g. *Crocodylus niloticus* by Cott, 1961; *C. johnstoni* by Webb & Manolis, 1983 and *C. porosus* by Webb & Messel, 1977). Many injuries sustained by crocodiles result from conflicts related to social behaviour and territoriality. There have been few studies of large crocodiles in the wild. Of 1345 specimens of *C. porosus* examined in one study, only 10 had snout-vent lengths greater than 150cm because, in wild populations, juveniles predominate (Webb & Messel, 1977). The least commonly recorded injuries in large crocodiles are those to the head. They account for only 25% of scarring in large crocodiles (TL >150cm, Webb & Messel, 1977). This is not surprising, because many crocodiles sustaining significant head injuries would die. One example (Webb & Manolis, 1989) was found dead, having lost the dorsal portion of its snout during combat.

The injuries sustained by the Nicholson R. crocodile were significant (Fig. 1). No estimate of when the jaw loss occurred can be made. The specimen was in good condition, with large fat reserves at the base of the tail and neck. It had been known in the area by locals, because of his distinctive head, for at least 18 years. Despite this, there had been no reports of a damaged lower jaw. The crocodile apparently survived largely by exploiting a cattle station rubbish dump where cattle offal, road-killed wallabies and feral pig carcasses were dumped. To do so, it walked close to 50m from the river. It would locate a carcass by smell, and go straight to it, regardless of the difficulty of the terrain. The crocodile would grasp the carcass in its jaws and return to the water by the easiest path, to feed. Abundant tracks indicated that this crocodile actively moved about on land several nights each month.

I thank Terri, Bob and Lyn Irwin; Dave and Jenny Hansen; Noel Oliver of Escott Station; Brad Jones; Lee Pang and Roger Bilney, for their assistance in compiling this information. Jeanette Covacevich, Queensland Museum helped prepare it for publication.

Literature Cited

- Cott, H.B. 1961. Scientific results of an inquiry into the ecology and economic status of the Nile crocodile *Crocodylus niloticus* in Uganda and northern Rhodesia. *Transactions of the Zoological Society of London* 29: 211-337.
- Glasby, C.J., Ross, G.J.B. & Beesley, P.L. (eds) 1993. *Fauna of Australia*. Vol. 2A. Amphibia & Reptilia. (Australian Government Publishing Service: Canberra).
- Iordansky, N.N. 1973. The skull of the Crocodilia. Pp. 201-262. In C. Gans & T.S. Parsons, (eds). *Biology of the Reptilia*. Vol. 4. (Academic Press: New York).
- Webb, G.J.W. & Manolis, S.C. 1983. *Crocodylus johnstoni* in McKinlay River Area, N.T. V. Abnormalities and Injuries. *Australian Wildlife Research* 10, 407-420.
1989. *Crocodiles of Australia*. (Reed: Sydney).
- Webb, G.J.W. & Messel, H. 1977. Abnormalities and injuries in the estuarine crocodile, *Crocodylus porosus*. *Australian Wildlife Research* 4: 311-319.

Stephen Irwin, Queensland Reptile Park, Glasshouse Mountains Tourist Drive, Beerwah, Queensland 4519, Australia; 23 february 1996.

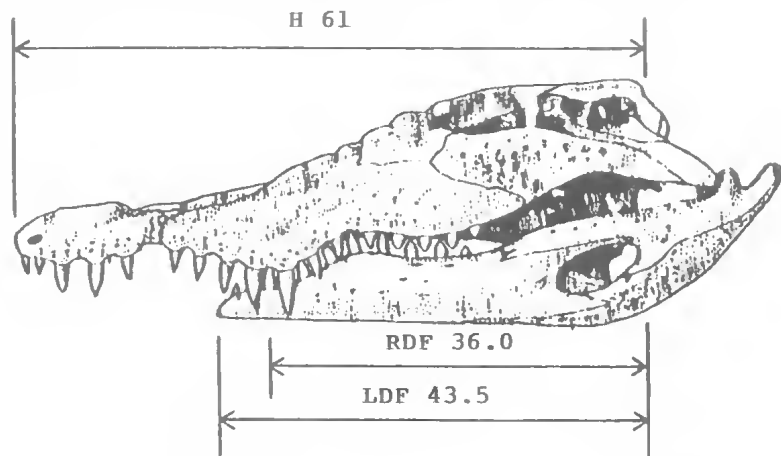


FIG. 1. Lateral view of injury with details of measurements taken at time of capture. Head (H). Left dentary fragment (LDF). Right dentary fragment (RDF). All measurements in centimetres